

*Case Study***Feline Idiopathic Cystitis (FIC) in A Mixed Breed Cat: Case Study in Malaysia****Syamira Syazuana Zaini\*, Amir Shauqi Ahmad Sukri and Azalea Hani Othman***Faculty of Veterinary Medicine, Universiti Putra Malaysia, 43400 Serdang, Selangor, Malaysia***ABSTRACT**

Feline idiopathic cystitis (FIC) is a common medical condition covering Feline Lower Urinary Tract Disease (FLUTD) in cats reported in many countries. However, there is a lack of prevalence studies reported in Malaysia. In this case report, a case of an FIC cat was presented at the University Veterinary Hospital, Universiti Putra Malaysia. The seven-month-old male mixed-breed cat had primary complaints of urine incontinence and haematuria. A thorough physical examination and diagnostic workup ruled out other causes, leading to the diagnosis of FIC. Based on the history provided by the owner, two weeks prior to the inappropriate urination, the cat moved into a new home, and the owner noticed that the cat appeared stressed and frequently urinated outside the litter box. In addition, the owner mentioned that dog bark noises were heard in the room where the cat was housed. Therefore, behavioural therapy (e.g., reconstitute the cat's home environment and increase the interaction between the owner and the cat) was also conducted as part of the medical intervention in this case. The owner reported no further recurrence of clinical signs. Thus, a complete recovery was achieved with a good prognosis.

*Keywords:* Behaviour therapy, cat, feline idiopathic cystitis, Malaysia, stress

**ARTICLE INFO***Article history:*

Received: 09 January 2024

Accepted: 04 March 2024

Published: 27 September 2024

DOI: <https://doi.org/10.47836/pjtas.47.4.03>*E-mail addresses:*

syamirasz@upm.edu.my (Syamira Syazuana Zaini)

shauqi097@gmail.com (Amir Shauqi Ahmad Sukri)

azalea@upm.edu.my (Azalea Hani Othman)

\* Corresponding author

**INTRODUCTION**

Feline idiopathic cystitis (FIC) is a bladder inflammation caused by unknown causes (Jones, 2009). The clinical signs of FIC are mostly similar to those of Feline Lower Urinary Tract Disease (FLUTD), such as haematuria, dysuria, pollakiuria, stranguria, periuria, and vocalisation when

urinating (Defauw et al., 2011). There are several risk factors relating to FIC: male, overweight, young to middle-aged cat and stress-causing events (He et al., 2022; Jones, 2009).

According to Hostutler et al. (2005), FIC is the most common covering about 55-69% of FLUTD cases, as reported in the United States of America (USA) (Lekcharoensuk et al., 2001), Germany (Dorsch et al., 2014), South Korea (Kim et al., 2018), Thailand (Piyarungsri et al., 2020), and Indonesia (Nururrozi et al., 2020). However, there is still a lack of FIC prevalence studies in Malaysia, which could be assumed to be as high as reported in other countries.

## CASE PRESENTATION

A seven-month-old male mixed-breed cat was presented to the University Veterinary Hospital (UVH), Universiti Putra Malaysia (UPM), with primary complaints of urinary incontinence and blood-streaked urine. According to the owner, they had moved to a new home two weeks prior to the medical issue, where the cat seemed stressed and frequently showed inappropriate urination (e.g., urinating outside of the litter box). Besides, the owner also mentioned frequent dog barking near the cat's room.

## Physical and Laboratory Evaluation

Upon physical examination, the cat's heart rate was within normal range (160 bpm), mild hypothermia (T: 37.2°C) and tachypnoea (respiratory rate: 96 bpm), which could be due to pain, anxiety and/or stress. Abdominal palpation revealed a small

urinary bladder; the physical examination was unremarkable.

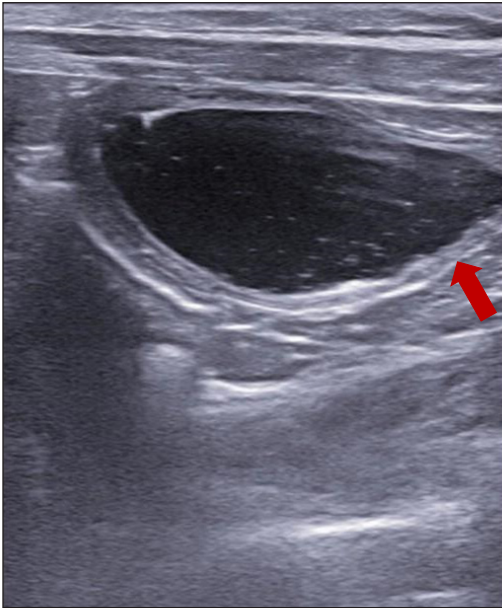
Routine haematology and serum biochemistry were largely unremarkable except for mild neutropenia ( $2.03 \times 10^9/L$ , normal range: 2.5–12.5). In serum biochemistry results, there was a high level of alkaline phosphatase (178 U/L, normal range: <80), mild hyperalbuminaemia (42.5 g/L, normal range: 25–40) and hyperproteinaemia (76.8 g/L, normal range: 55–75).

Cystocentesis was performed, and the collected urine was sent for urinalysis, urine smear and urine culture. The urine appeared pale reddish with a turbidity of 3+. The chemical properties of the urine showed proteinuria at 3+. Microscopically, there were numerous erythrocytes and about 10–15 leukocytes. Bacterial culture yielded no growth.

An abdominal radiograph and ultrasound revealed a small urinary bladder with no urethral abnormalities and urolith (Figure 1). There was mild thickening of the bladder wall, an irregular pattern at the distal part of the bladder wall, and snowflake echogenicity in the urinary bladder (Figure 2).

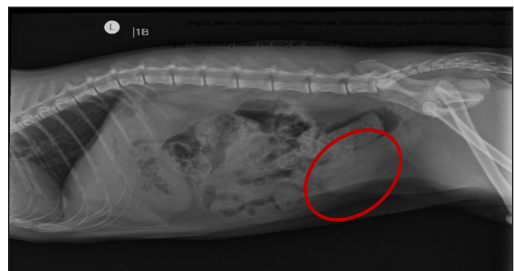

Figure 1. Small urinary bladder (red circle) with absence of cystolith on the left lateral view of radiograph



*Figure 2.* Irregular pattern at the distal part of the bladder wall (red arrow) and snowflake echogenicity in the bladder

### Behavioural History

According to the owner, they had moved to a new house two weeks prior to the inappropriate urination incident. At the previous house, the cat stayed with another senior cat, but the owner noticed no conflict. In the present house, there was only one cat (the patient), and the cat was placed in a room where all the basic resources (e.g., litter box, resting place, water and feeding bowl) were provided. The owner also reported that a dog lived in a nearby apartment, exactly next to the cat's room. The dog barked frequently, and the noise was significant. Therefore, a number of environmental stressors could be described for this cat, including moving to a novel environment, noise from dog barking, and restricted movement.

### Diagnosis

Based on the medical investigation, no other potential causes of FLUTD (e.g., urolithiasis, urethral plug, and bacterial cystitis) led to the diagnosis of FIC.

The behavioural history suggested that the cat had likely experienced stress due to a few environmental factors. Plus, moving to a novel environment, which in this case moved to a new house, could have restricted the cat from expressing its normal behaviours or 'coping' with potential stressors that might arise. In addition, a new environment, where the dog was barking consistently next to the cat's room could have made the cat feel threatened, and the stressor was unavoidable.

### Treatment

#### *Medical Management*

On the first visit, the cat was treated with N-acetyl D-glucosamine (Cystaid®, VetPlus Ltd., United Kingdom) as a glycosaminoglycans (GAG) supplement, serratiopeptidase (Danzen®, Dynapharm Sdn. Bhd., Malaysia) as an anti-inflammatory, and amoxicillin + clavulanic acid (Augmentin™, GlaxoSmithKline, France) as a broad-spectrum antibiotic for two weeks.

A follow-up visit was scheduled for the cat, and according to the owner, the cat's stranguria persisted. Besides Cystaid® and Danzen®, the veterinarian in charge added diazepam (Duopharma Sdn. Bhd., Malaysia) and meloxicam (Pharmaniaga Manufacturing Berhad,

Malaysia) for urethral muscle relaxant and pain management.

### ***Behaviour Therapy***

Since a few potential environmental stressors that led to this cat's medical issue were identified, so a few alternatives were discussed. The owner was instructed to move the cat to a room or area where the noise from dog barking could be minimised to reduce the stress caused by dog barking. In the potential new area, the basic environmental resources should be instituted, such as comfortable bedding for rest and sleep, a clean litter tray, a feed and water bowl and a hiding place. The owner was also advised to increase interaction with the cat, such as play, as this could encourage a positive human-cat relationship and reduce anxiety.

### ***Progress and Prognosis***

The owner was very compliant in following management and behavioural advice. There was no further complaint about the cat's inappropriate urination, and this case was considered to have a good prognosis.

## **DISCUSSION**

FIC is an inflammation of the bladder due to unknown causes (Jones, 2009), which is only diagnosed when no agents or causes are identified after several diagnostic workups (Hostutler et al., 2005). FIC can be both obstructive and non-obstructive. The clinical signs of FIC are similar to FLUTD, such as haematuria, dysuria, pollakiuria, stanguria,

periuria, vocalisation when urinating, and over-grooming of the genital area (Defauw et al., 2011). A study indicates several risk factors relating to FIC, such as male, overweight, fed with a dry diet only, young to middle-aged cats and stress-causing events (He et al., 2022; Jones, 2009).

Hostutler et al. (2005) stated that FIC is the most common, covering about 55-69% of FLUTD cases, such as studies on the prevalence of FLUTD caused by FIC ranging from 55-66% reported in the USA (Lekcharoensuk et al., 2001), Germany (Dorsch et al., 2014), South Korea (Kim et al., 2018), Thailand (Piyarungsri et al., 2020), and Indonesia (Nururrozi et al., 2020). However, there is a lack of study or data on the prevalence of FIC in Malaysia, which could be assumed as high as reported in other countries. Therefore, further study in this field is needed as this could give an idea of how we can manage it well, especially from both human and cat perspectives.

Currently, the pathophysiology of FIC is still unclear. There are a few hypotheses on the development of FIC. Comprehensive theories suggest that FIC is caused by changes in the nervous system of cats and their inability to cope with environmental stress (He et al., 2022) and that cats with FIC have smaller adrenal glands and a blunted stress response and produce higher levels of catecholamines than others without FIC (He et al., 2022). It causes changes in the interaction between the neuron and the bladder, aggravated by noxious substances in the urine. It may be increased further by altered interactions with the bladder's

protective GAG layer (Forrester & Towell, 2015). This response is called neurogenic inflammation (Buffington et al., 1996). The neurogenic inflammation begins with the stimulation of the C-fibres via central or local triggers. It can result in the release of neuropeptides such as substance P, which can cause pain, vasodilation of intramural blood vessels, increased vascular and bladder-wall permeability, submucosal oedema, smooth muscle contraction, and mast cell degranulation (Buffington et al., 1996; Chew & Buffington, 2013). Mast cell degranulation produces several inflammatory mediators, such as histamine, heparin, serotonin, cytokines, and prostaglandins, which can exacerbate the effects of the C-fibres. Many of the alterations observed in FIC can thus be explained by C-fibre stimulation and the ongoing neurogenic inflammation.

FIC is often difficult for clients to comprehend because, in many cases, the underlying cause may not be identified. It led to the difficulty of diagnosing FIC as the diagnosis will be announced once other potential differential diagnoses (e.g., urolithiasis, urinary tract infection, and urethral stricture) are ruled out (Hostutler et al., 2005). It is thought to be significantly influenced by environmental stress, for example, conflict in multi-cat households, moving to a novel environment or environmental changes such as construction work, bad weather, the arrival of new family members or pets, improper placement and cleanliness of the litter box, owner stress, a sudden change in diet, or a change in the cat's access to the outside (Cameron et al., 2004; Jones, 2009).

Since stress factors are crucial in the development of FIC, prevention by management is the best method to reduce the recurrence (Westropp & Buffington, 2004). It can be achieved through multimodal environmental modification (MEMO) (He et al., 2022; Lund & Eggertsdóttir, 2019). MEMO can substantially reduce lower urinary tract symptoms, fearfulness, and nervousness in cats with idiopathic cystitis. According to Buffington et al. (2006), there are five essential elements for a healthy feline environment in MEMO. The first pillar is to offer a safe environment for cats by providing specific hiding spots such as cat trees and cat tunnels. The second pillar entails providing multiple and distinct supplies for the food and drink bowl, litter box, and scratching area. It may help to mediate inter-cat conflicts by reducing competition for resources. The third pillar encourages play and predatory behaviour in cats by utilising interactive cat toys that imitate the cat's natural hunting impulse. The fourth pillar is owner must provide a good, consistent human-cat social connection: each cat in a multi-cat household should receive personalised attention without interference from other cats. Finally, the fifth pillar is to develop an environment that values the cat's sense of smell. It can be accomplished by minimising strong odours, detergents, and scented litter, which interfere with the cat's sensory awareness and odours associated with its regular environment (Ellis et al., 2013).

In the current case, the cat was successfully managed medically, plus



behavioural therapy. As described, a few potential environmental stressors caused FIC in the cat, such as moving to a new house, encountering an unfamiliar place, and experiencing loud noise from the dog's barking. The MEMO five elements were applied accordingly based on the issues identified. For example, in the current case, the owner was advised to move the cat to a room or area where the noise from the dog barking could be minimised. In the potential new area, the basic environmental resources were instituted, such as comfortable bedding for rest and sleep, a clean litter tray, a feed and water bowl, and a hiding place. The owner was also advised to increase interaction with the cat, such as play, as this could encourage a positive human-cat relationship and reduce anxiety. As the owner was very compliant in following management and behavioural advice, there is no further complaint about the cat's inappropriate urination. Therefore, in future FLUTD, due to high suspicion of FIC, the case is encouraged to be managed in medical and behavioural therapy.

## CONCLUSION

In the current case, inappropriate urination in a cat was highly suspected due to FIC, and it was treated using both medical and behavioural therapy. Inappropriate urination is required when investigating the potential cause of the issue as it helps the institution develop a proper plan for managing the issue successfully. Plus, it could improve the cat's well-being and reduce the chance of recurrence.

## ACKNOWLEDGEMENTS

The authors thank the University Veterinary Hospital, Universiti Putra Malaysia (UPM), and the laboratory staff of the Veterinary Laboratory Service Unit, UPM, for their tremendous work, quality testing, and services in managing this case. Thanks to the Research Management Centre (RMC), UPM, for supporting the journal publication fund.

## REFERENCES

- Buffington, C. A. T., Chew, D. J., & DiBartola, S. P. (1996). Interstitial cystitis in cats. *Veterinary Clinics of North America: Small Animal Practice*, 26(2), 317–326. [https://doi.org/10.1016/S0195-5616\(96\)50212-3](https://doi.org/10.1016/S0195-5616(96)50212-3)
- Buffington, C. A. T., Westropp, J. L., Chew, D. J., & Bolus, R. R. (2006). Clinical evaluation of multimodal environmental modification (MEMO) in the management of cats with idiopathic cystitis. *Journal of Feline Medicine and Surgery*, 8(4), 261–268. <https://doi.org/10.1016/j.jfms.2006.02.002>
- Cameron, M. E., Casey, R. A., Bradshaw, J. W. S., Waran, N. K., & Gunn-Moore, D. A. (2004). A study of environmental and behavioural factors that may be associated with feline idiopathic cystitis. *Journal of Small Animal Practice*, 45(3), 144–147. <https://doi.org/10.1111/j.1748-5827.2004.tb00216.x>
- Chew, D., & Buffington, C. A. T. (2013). *Pandora syndrome: It's more than just the bladder*. [https://justcatsonline.com/wp-content/uploads/2023/05/Pandora\\_Syndrome.pdf?ver](https://justcatsonline.com/wp-content/uploads/2023/05/Pandora_Syndrome.pdf?ver)
- Defauw, P. A., Van de Maele, I., Duchateau, L., Polis, I. E., Saunders, J. H., & Daminet, S. (2011). Risk factors and clinical presentation of cats with feline idiopathic cystitis. *Journal of Feline Medicine and Surgery*, 13(12), 967–975. <https://doi.org/10.1016/j.jfms.2011.08.001>

- Dorsch, R., Remer, C., Sauter-Louis, C., & Hartmann, K. (2014). Feline lower urinary tract disease in a German cat population: A retrospective analysis of demographic data causes and clinical signs. *Tierärztliche Praxis Ausgabe K: Kleintiere / Heimtiere*, 42(4), 231–239. <https://doi.org/10.1055/s-0038-1623769>
- Ellis, S. L. H., Rodan, I., Carney, H. C., Heath, S., Rochlitz, I., Shearburn, L. D., Sundahl, E., & Westropp, J. L. (2013). AAFP and ISFM feline environmental needs guidelines. *Journal of Feline Medicine and Surgery*, 15(3), 219–230. <https://doi.org/10.1177/1098612X13477537>
- Forrester, S. D., & Towell, T. L. (2015). Feline idiopathic cystitis. *Veterinary Clinics of North America: Small Animal Practice*, 45(4), 783–806. <https://doi.org/10.1016/j.cvsm.2015.02.007>
- He, C., Fan, K., Hao, Z., Tang, N., Li, G., & Wang, S. (2022). Prevalence, risk factors, pathophysiology, potential biomarkers and management of feline idiopathic cystitis: An update review. *Frontiers in Veterinary Science*, 9, 900847. <https://doi.org/10.3389/fvets.2022.900847>
- Hostutler, R. A., Chew, D. J., & DiBartola, S. P. (2005). Recent concepts in feline lower urinary tract disease. *Veterinary Clinics of North America: Small Animal Practice*, 35(1), 147–170. <https://doi.org/10.1016/j.cvsm.2004.08.006>
- Jones, A. (2009). Feline Lower Urinary Tract Disease (FLUTD): An overview. *Veterinary Nursing Journal*, 24(3), 21–24. <https://doi.org/10.1080/17415349.2009.11013073>
- Kim, Y., Kim, H., Pfeiffer, D., & Brodbelt, D. (2018). Epidemiological study of feline idiopathic cystitis in Seoul, South Korea. *Journal of Feline Medicine and Surgery*, 20(10), 913–921. <https://doi.org/10.1177/1098612X17734067>
- Lekcharoensuk, C., Osborne, C. A., & Lulich, J. P. (2001). Epidemiologic study of risk factors for lower urinary tract diseases in cats. *Journal of the American Veterinary Medical Association*, 218(9), 1429–1435. <https://doi.org/10.2460/javma.2001.218.1429>
- Lund, H. S., & Eggertsdóttir, A. V. (2019). Recurrent episodes of feline lower urinary tract disease with different causes: possible clinical implications. *Journal of Feline Medicine and Surgery*, 21(6), 590–594. <https://doi.org/10.1177/1098612X18783839>
- Nururrozi, A., Yanuartono, Y., Sivananthan, P., & Indarjulianto, S. (2020). Evaluation of lower urinary tract disease in the Yogyakarta cat population, Indonesia. *Veterinary World*, 13(6), 1182–1186. <https://doi.org/10.14202/vetworld.2020.1182-1186>
- Piyarungsri, K., Tangtrongsup, S., Thitaram, N., Lekklar, P., & Kittinuntasilp, A. (2020). Prevalence and risk factors of feline lower urinary tract disease in Chiang Mai, Thailand. *Scientific Reports*, 10, 196. <https://doi.org/10.1038/s41598-019-56968-w>
- Westropp, J. L., & Buffington, C. A. T. (2004). Feline idiopathic cystitis: Current understanding of pathophysiology and management. *Veterinary Clinics of North America: Small Animal Practice*, 34(4), 1043–1055. <https://doi.org/10.1016/j.cvsm.2004.03.002>

